
Scleral fixation of dislocated posterior chamber intraocular lenses

Temporary haptic externalization through a clear corneal incision

Gregg T. Kokame, MD, Izumi Yamamoto, MD, Huck Mandel, MD

Purpose: To report the results of managing dislocated posterior chamber intraocular lenses (PC IOLs) by externalizing the haptics through a clear corneal incision.

Setting: The Retina Center at Pali Momi, Aiea, Hawaii, USA.

Methods: This retrospective consecutive series comprised cases in which a dislocated PC IOL was managed with pars plana vitrectomy. With this method, the dislocated PC IOL is retrieved and stabilized in the anterior chamber. The haptic is externalized through a clear corneal incision for suture knot placement and then reinserted. A scleral fixation suture is placed 1.25 mm posterior to the limbus under a scleral flap.

Results: The study included 14 eyes of 14 patients with a minimum follow-up of 6 months (median 15.4 months). There were 2 subluxated PC IOLs, 11 posteriorly dislocated PC IOLs, and 1 in-the-bag IOL dislocation. Postoperative vision and/or visual symptoms were stable or improved in 86% of eyes. Two eyes had worse vision caused by conditions not related to surgery including chronic cystoid macular edema from latanoprost use and optic atrophy. All IOLs were well fixated and stable, although 1 eye with asymmetric haptics had a slightly tilted IOL.

Conclusions: Dislocated PC IOL management by externalizing the haptic through a clear corneal incision stabilized the IOL in the anterior chamber, minimized intraocular operative manipulations, and allowed easier placement of the opposite haptic over residual capsule, if available. Stable fixation was achieved without dislocation or IOL-related complications recurring.

J Cataract Refract Surg 2004; 30:1049–1056 © 2004 ASCRS and ESCRS

Dislocation of intraocular lenses (IOLs) has been noted throughout the history of IOL implantation in cataract surgery and remains a challenging surgical

management problem. Surgical management options include removing, exchanging, and repositioning the IOL.^{1–3} If residual capsule support is adequate, a posterior chamber (PC) IOL can be repositioned over residual capsule in the ciliary sulcus. If capsule support is inadequate, the dislocated PC IOL can be repositioned using scleral fixation sutures^{4–6} or exchanged for a scleralfixated PC IOL or anterior chamber (AC) IOL.^{7,8}

Repositioning dislocated PC IOLs has the advantage of using the same lens that provided functional vision before it became dislocated; it also obviates the need to make a large limbal incision to remove or exchange the IOL. Larger limbal incisions increase the risk for postoperative astigmatism. Many techniques for

Accepted for publication September 17, 2003.

From the Division of Ophthalmology, Department of Surgery, University of Hawaii School of Medicine (Kokame, Yamamoto), Honolulu, and the Retina Center at Pali Momi, an affiliation of Hawaii Pacific Health (Kokame, Yamamoto, Mandel), Aiea, Hawaii.

None of the authors has a financial or proprietary interest in any material or method mentioned.

Reprint requests to Gregg T. Kokame, MD, Medical Director, The Retina Center at Pali Momi, 98-1079 Moanalua Road, Suite 470, Aiea, Hawaii 96701, USA. E-mail: retinahawaii@aol.com.

scleral fixation of dislocated IOLs have been described. They can be divided into 2 general categories: (1) techniques in which a suture loop is created around the haptic with surgical maneuvers around the dislocated PC IOL inside the eye⁹⁻²²; (2) techniques in which the haptic is externalized and a tightened suture knot is placed around the haptic outside the eye.⁴⁻⁶

In 1992, Chan⁴ introduced the technique of temporary haptic externalization for placement of scleral fixation sutures to minimize intraocular manipulations and allow easy suture placement around the haptic of the dislocated PC IOL. Haptics were externalized through pars plicata sclerotomy sites, suture loops were placed around the haptics externally, and the haptics were reinserted for scleral fixation at the pars plicata sclerotomies. Kokame and coauthors⁵ describe a modified technique of haptic externalization in which the PC IOL is retrieved during pars plana vitrectomy (PPV) and brought back into a stable position in the anterior chamber. The haptic of the dislocated PC IOL is externalized under direct visualization through a small clear corneal incision for placement of fixation sutures.

This study evaluated the visual outcomes, anatomic success of repositioning, and postoperative complications after the haptics of dislocated PC IOLs were temporarily externalized through a clear corneal incision.

Patients and Methods

This retrospective review comprised a consecutive series of patients who had surgical management of a dislocated PC IOL by externalization of the haptic through a clear corneal incision. All cases were performed by 1 vitreoretinal surgeon (G.T.K.) in a retinal consultation practice at the Retina Center at Pali Momi, Hawaii, between January 2000 and July 2002. The study was reviewed and approved by the Institutional Review Board of Hawaii Pacific Health, with which the Retina Center at Pali Momi is affiliated. All cases used a modified technique of temporary haptic externalization through a clear corneal incision for placement of scleral fixation sutures as described previously.⁵

Preoperatively, eyes with a dislocated PC IOL were evaluated at the slitlamp for the presence of residual capsule support with tangential views to look for capsule remnants behind the iris. If there were at least 5 to 6 clock hours of residual capsule for the support of 1 haptic, the position of scleral fixation for the other haptic was planned for 180 degrees from the center of residual capsule support. To determine the stability of a subluxated or partially dislocated PC IOL, the IOL's position was evaluated with the patient in

an upright position at the slitlamp and in a supine position for indirect ophthalmoscopy.

Initially, inferior-based triangular scleral flaps were made at the planned scleral fixation site. Within the bed of the scleral flap, a 20-gauge sclerotomy was made 1.25 mm posterior to limbus. A clear corneal incision was made approximately one-half clock hour counterclockwise from each fixation sclerotomy within the bed of the scleral flap (Figure 1). A standard 3-port PPV was performed with separate sclerotomies 3.0 mm posterior to the limbus.

If posteriorly dislocated, the PC IOL was retrieved from the vitreous cavity with a straight vitreous forceps; if only subluxated, it was stabilized in the anterior vitreous cavity with a straight vitreous forceps or IOL positioning hooks (Figure 2). The IOL was then anteriorly subluxated into the anterior chamber, and 1 haptic was externalized through the clear corneal incision under direct visualization. To do this, the surgeon grasped the end of the haptic through the clear corneal incision with a long, angled implantation forceps (Figure 2). In this position, the IOL was stable in the anterior segment and in a normal implantation position.

The end of the haptic was cauterized to create a bulb to prevent the suture from slipping.²³ A 10-0 polypropylene (Prolene®) suture loop attached to a long, curved needle (PC-9, Alcon Laboratories) was placed and tightened around the externalized haptic (Figure 3). The needle was passed backward, with the blunt end through the clear corneal incision to position the suture through the pupil and posterior to the iris, where a separate instrument placed through the fixation sclerotomy could retrieve the suture 1.25 mm posterior to the limbus (Figure 4). The needle was then cut off (Figure 5), and the sutures attached to the haptic were pulled through the fixation sclerotomy under the scleral flap (Figures 6 and 7). The externalized haptic was then reimplemented, and the suture was tightened through the fixation sclerotomy (Figure 8). A separate 10-0 Prolene suture bite was made under the scleral flap to close the sclerotomy and to tie it together with the retrieved fixation sutures (Figure 9) to create the scleral fixation. The scleral flap was closed over the tied fixation suture. If the other haptic required scleral fixation, the same technique was used. In cases with adequate residual capsule for support of 1 haptic, only 1 fixation sclerotomy and 1 clear corneal incision were prepared and residual capsule support was used for the other haptic.

All eyes had a complete ophthalmic examination including Snellen best corrected visual acuity (BCVA) preoperatively and postoperatively. Cases with fewer than 6 months of postoperative follow-up were excluded from the study. Patients presenting with active coexisting ocular disease that compromised vision were also excluded to allow accurate assessment of the primary visual outcome of the surgery.

The following preoperative data were evaluated: the patient's age and sex, involved eye, preexisting ocular pathology, preoperative BCVA, refractive error, IOL composition and design, time from initial cataract surgery with IOL implanta-

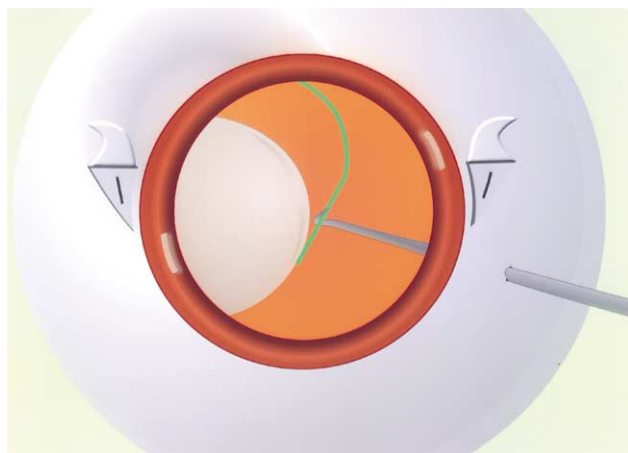


Figure 1. (Kokame) Surgeon's view. The dislocated PC IOL is retrieved from the vitreous cavity and then supported in the anterior vitreous cavity with a Sinsky hook.

tion to IOL dislocation, and time from IOL dislocation to the repositioning surgery. Intraoperative data included surgical technique of scleral fixation of the dislocated IOL, the number of scleral fixation sutures, the use of residual peripheral capsule for fixation, additional procedures performed concomitantly, and intraoperative complications. Postoperative data included the best postoperative BCVA and the BCVA at the

final examination, refractive error, position of the repositioned IOL, and postoperative complications.

Results

During the study, 20 eyes had repositioning of a dislocated PC IOL by clear corneal externalization of the haptic. Of these, 3 were excluded because they had a follow-up of fewer than 6 months and 3, because of coexisting ocular disease affecting vision. Conditions for exclusion included active proliferative diabetic retinopathy and retinal detachment. None of the 6 excluded eyes had complications related to the IOL repositioning or malpositioning of the repositioned PC IOL at the last follow-up. Therefore, this study included 14 eyes (8 left, 6 right) of 14 patients (13 men, 1 woman) with a mean follow-up of 15.4 months (range 6 to 30 months). The patients' ages ranged from 50 to 83 years.

All patients had visual symptoms including sudden loss of vision, marked glare, distorted or blurred vision, double vision, and floaters. Preexisting ocular conditions included glaucoma in 3 eyes, nonproliferative diabetic retinopathy in 2 eyes, quiescent proliferative diabetic reti-



Figure 2. (Kokame) Cross-sectional sagittal view. After the dislocated PC IOL is grasped with a straight, serrated, vitreous forceps, the PC IOL is anteriorly subluxated into the anterior chamber through the pupil and over the iris. One haptic is externalized through a clear corneal incision under direct visualization after the end of the haptic is grasped through the corneal incision with a long, angled, implantation forceps.



Figure 3. (Kokame) Cross-sectional sagittal view. The end of the haptics are cauterized to create a bulb to prevent the suture from slipping. A 10-0 Prolene suture loop double attached to a long curved needle is looped and tightened into a secure knot around the externalized haptic.




Figure 4. (Kokame) Cross-sectional sagittal view. The blunt side of the long curved needle is used to pass the suture through the clear corneal incision and posterior to the iris, where the sutures are retrieved with a vitreous forceps with an opening proximal to the end-gripping jaws through the fixation sclerotomy.

nopathy in 1 eye, and successfully repaired previous retinal detachment in 4 eyes. The preoperative BCVA was 20/30 in 5 eyes, 20/40 to 20/200 in 3 eyes, and worse than 20/200 in 6 eyes. The median refractive error was +8.00 diopters (D) (range -1.25 to +11.25 D).

The type of IOL originally implanted was obtained from anterior segment surgeons, if available. The haptics

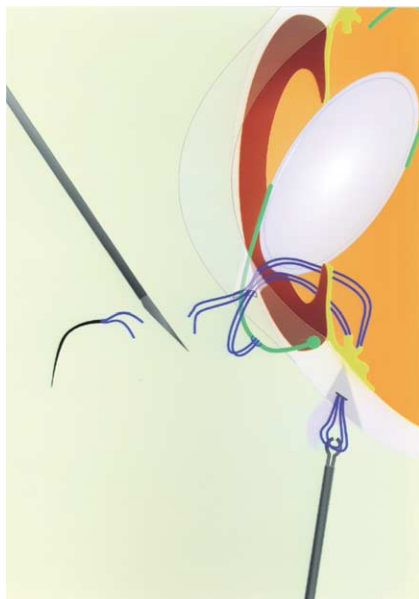

Figure 5. (Kokame) Cross-sectional sagittal view. The long curved needle is cut off, and the sutures around the haptic are pulled through the fixation sclerotomy.



Figure 6. (Kokame) Cross-sectional sagittal view. The haptic with the tightened fixation suture is ready to be reimplanted into position in the ciliary sulcus.

of the dislocated IOLs were polypropylene in 3 eyes, poly(methyl methacrylate) (PMMA) in 10, and unknown in 1. The optics were silicone in 2 eyes, PMMA in 4, acrylic in 6, and unknown in 3. No eye had a plate-haptic silicone lens. Two PC IOLs were subluxated, 11 were dislocated into the vitreous cavity, and 1 was in an intact capsular bag. One eye had a previous procedure for a dislocated PC IOL performed elsewhere that involved exchange of the original PC IOL for a sulcus-fixed PC IOL over residual capsule without sutures. None of the eyes had previous scleral fixation sutures.

The interval between the PC IOL implantation and IOL displacement was intraoperative in 2 eyes, 2 to 4 weeks in 1 eye, 1 to 6 months in 4 eyes, and more than 6 months in 7 eyes (range 28 months to 20 years); the mean interval was 4.4 years. Most cases of PC IOL dislocation occurred spontaneously without a recent precipitating event; however, 1 eye had a recent scleral buckle and vitrectomy for retinal detachment repair. No patient reported blunt ocular trauma. The mean interval between the IOL displacement and repositioning surgery was 24.5 days (range 10 days to 2 months).

During the repositioning surgery, 5 eyes had scleral fixation sutures placed around both haptics and 9 eyes had 1 scleral fixation suture with the other haptic supported by residual capsule. For in-the-bag PC IOL dislocation, the capsule was dissected off the haptics before both haptics were scleral fixated. Perfluorocarbon liquid was not used in any case. During repositioning surgery, 2 eyes had revision of the previous clear corneal incision used for cataract surgery, 2 had synechiolysis, and 1 had pterygium and lipoma excision by an anterior segment surgeon. One eye developed localized iridodiolysis and hyphema during synechiolysis that was self-

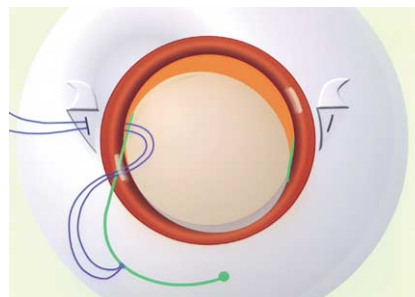


Figure 7. (Kokame) Surgeon's view. The sutures around the haptic pass through the clear corneal incision through the pupil, posterior to the iris, and out the fixation sclerotomy.

limited and allowed successful reformation of the ciliary sulcus.

Postoperative visual acuity was stable or improved in 12 eyes (86%). The BCVA improved by 2 or more Snellen lines in 7 eyes. All 5 patients with a preoperative BCVA of 20/30 or better had improvement in visual

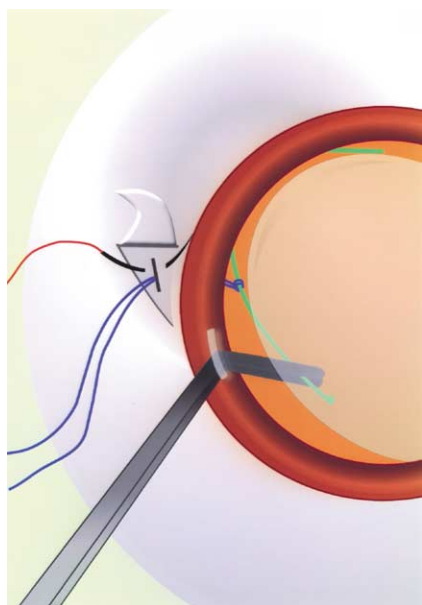


Figure 8. (Kokame) Surgeon's view. The externalized haptic is reimplanted through the clear corneal incision, which is located one-half clock hour counterclockwise from the planned fixation site.

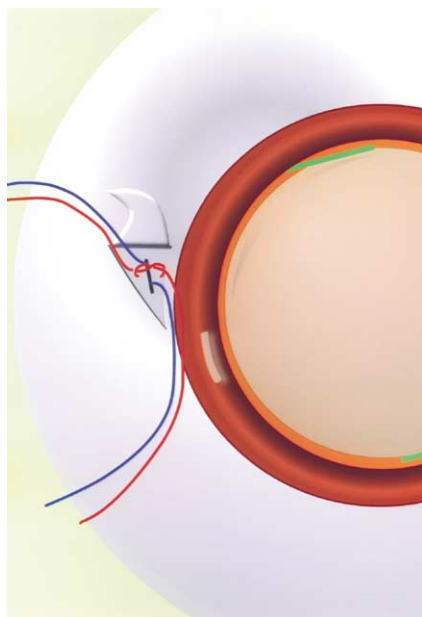


Figure 9. (Kokame) Surgeon's view. A separate 10-0 Prolene suture bite (red sutures) is made under the scleral flap to close with the sclerotomy and to tie together with the retrieved fixation sutures (blue sutures) to create the scleral fixation.

symptoms including blurred vision, marked glare, and double vision. Two eyes had worse acuity as a result of unrelated conditions. One eye had initial improvement in acuity but developed chronic cystoid macular edema (CME) in the late postoperative period after the patient began taking latanoprost for glaucoma. One patient had poor vision and bilateral optic atrophy after a stroke with an occipital infarct, which occurred 1 year after IOL repositioning. The Snellen BCVA at the last postoperative visit was 20/40 or better in 10 eyes, 20/50 to 20/200 in 2 eyes, and worse than 20/200 in 2 patients. The patients with a BCVA worse than 20/200 had a median refractive error of -2.00 D (range plano to -5.00 D). All IOLs were stably fixated except in 1 eye in which the IOL was slightly tilted. This IOL had an asymmetric haptic at the time of repositioning surgery. No IOL dislocated again during the follow-up.

Postoperative complications after IOL repositioning included mild corneal striae with a clear cornea (7 eyes), self-limited CME (1 eye), chronic CME (1 eye), mild self-limited vitreous hemorrhage (2 eyes), and spontaneously resolved corneal edema (1 eye). Postoperative retinal detachment, iris capture of the optic, iris atrophy, new-onset glaucoma, uveitis, or bullous keratopathy did not occur in any case.

Discussion

In this consecutive surgical series, dislocated PC IOLs were managed by PPV, stabilization of the PC IOL in the anterior chamber, and externalization of the haptic through a clear corneal incision. Pars plana vitrectomy was used because the dislocated PC IOLs were unstable or posteriorly dislocated into the vitreous cavity. Pars plana vitrectomy provides a stable operative environment within a closed system and provides continuous pars plana infusion to maintain intraocular pressure. This allows controlled removal of vitreous before the IOL is manipulated, minimizing the risk for vitreous traction during intraocular surgical maneuvers. The closed system and undistorted cornea provide optimal visualization during retrieval of the unstable dislocated PC IOL and accurate visualization of the peripheral retina for associated retinal tear or retinal detachment.²⁻⁴

To reposition dislocated PC IOLs in eyes with inadequate residual capsule support, scleral fixation sutures can be used around the haptic and fixated to the

sclera. Many techniques have been developed to create a loop around the haptic by intraocular maneuvers; however, these can be cumbersome because of the unstable and mobile dislocated PC IOL and because multiple instrument passes are required to create a loop around the haptic. Internal looping scleral fixation techniques include multiple needle passages through sclerotomies⁹⁻¹¹ or through paracentesis sites¹²⁻¹⁴ and looping the haptic by using a suture loop created using a threaded needle,^{15,16} by holding a suture with a forceps,¹⁷ by grasping the haptics with an externally pretied loop,¹⁸⁻²⁰ or by lassoing the haptic with a double-loop cow-hitch knot.^{21,22} Because of the technical difficulty of these maneuvers and the risk for IOL redislocation caused by the haptics slipping from the suture loop, exchange of the dislocated PC IOL for an AC IOL with flexible open-ended haptics has been recently advocated.^{7,8}

Chan⁴ first described externalization of the haptic of dislocated PC IOLs to allow retrieval of the IOL with optimal visualization during PPV. This technique simplified more secure placement of the suture knot around the haptic by externalizing it through a pars plicata fixation sclerotomy.^{2,6} Kokame and coauthors⁵ introduced a modification of this technique in which the dislocated PC IOL is moved up into the anterior chamber and the haptic is externalized through a clear corneal incision. Externalizing the haptic, as performed in our surgical series, stabilizes the PC IOL in the anterior chamber after it is retrieved from the vitreous cavity and provides optimal visualization of the externalization of the haptic through a small clear corneal incision. With pars plicata externalization behind the iris, the externalization of the haptic is blind and there is a risk for haptic damage. No haptic in this series of clear corneal externalization was damaged. In addition, in pars plicata externalization, the haptic must be dragged close to the vitreous base, risking peripheral retinal tear or detachment. With pars plicata externalization, the dislocated PC IOL is unstable and more posteriorly positioned in the anterior vitreous cavity. In contrast, once 1 haptic is externalized through a clear corneal incision, the previously unstable dislocated PC IOL becomes stable and is in a normal implantation position in the anterior chamber. This simplifies placement of the nonexternalized haptic over residual capsule support, if available, as was done in 64% of the cases in our series. In eyes without residual capsule support,

both haptics can be externalized through separate clear corneal incisions and scleral fixated, as done in 36% of cases.

Fixating sutures outside the eye provides a more secure, tighter knot around the haptic than looping a suture around the haptic of an unstable IOL inside the eye. In addition, the end of the externalized haptic can be treated with cautery to create a bulb on the end, decreasing the risk for slippage during reinsertion and repositioning.^{2-6,23} These advantages may lower the incidence of a second dislocation. No IOL in our series became dislocated again except in 1 eye in which the IOL was tilted. The IOL appeared to be well centered after the vitrectomy, repositioning, and scleral fixation of both haptics. However, preexisting asymmetry of the haptics was noted by the cataract surgeon at the time of initial IOL implantation and is probably why the IOL tilted. This patient did not require further surgery and maintained useful vision even with the tilted lens. No eye required additional surgery for recurrent IOL dislocation.

In our series of dislocated PC IOLs repositioned with internal looping techniques over a 10-year period, the IOL became dislocated again in 18% of 34 eyes (G.T. Kokame, MD, M. DeLeon, MD, "Pars Plana Microsurgical Management of Dislocated Lens Implants," presented at the annual meeting of the American Academy of Ophthalmology, Dallas, Texas, USA, October 2000). In a series of 16 eyes reported by Sarrafizadeh et al.,⁸ dislocation requiring reoperation developed in 25% (4 eyes) of IOLs initially fixated with scleral fixation sutures.

Posterior chamber IOL torsion and decentration can be minimized by accurate suture placement in the ciliary sulcus. We recommend fixation sclerotomy sites 1.25 mm posterior to the limbus. Other measures include adequate excision of capsule remnants,¹ placement of fixation sclerotomies precisely 180 degrees from each other, and tying fixation sutures equidistant from the ends of each haptic⁴ and at the most peripheral site of the greatest haptic diameter.

If there is adequate residual capsule support, especially in the presence of an intact anterior capsulorhexis, repositioning the IOL over residual capsule alone is appropriate and the least traumatic procedure. No eye in our series had enough residual capsule support to allow repositioning without at least 1 scleral fixation

suture. Controversy arises in the absence of adequate capsule support. Two commonly performed procedures are repositioning the existing dislocated PC IOL with scleral fixation sutures and exchanging the dislocated PC IOL for an AC IOL. In the series of Sarrafizadeh et al.,⁸ there was no difference in visual acuity between eyes having the IOL repositioned and those having an IOL exchange. The complication rates were similar between the 2 groups. The authors believe that an important reason to consider IOL exchange, even though it requires a large limbal incision and risks corneal endothelial damage, is the technically demanding nature of IOL repositioning with scleral fixation. Management of dislocated PC IOLs with the use of clear corneal externalization of the haptic, the technique used in our series, is less technically demanding because it stabilizes the IOL in the anterior chamber and puts it back into a position that enables the surgeon to easily recenter it.

A scleral-fixated PC IOL may be preferred over an AC IOL in eyes with certain conditions including compromised cornea, peripheral anterior synechias, shallow anterior chamber, and glaucoma. Even if the AC IOL has open, flexible, loop haptics, there may still be a long-term risk for damage to the corneal endothelium; also, a scleral-fixated PC IOL may be preferred in younger patients with a life expectancy greater than 10 years.^{24,25} Yet, exchange of a dislocated PC IOL for an AC IOL with open-loop haptics has been shown to be well tolerated.^{7,8} Open-loop haptics lead to significantly fewer complications than the rigid or closed-loop haptics that were previously used. However, some studies show complications associated with AC IOLs with open-loop haptics over a longer follow-up.^{26,27} A study of primary implantation of open-loop AC IOLs with a follow-up of almost 10 years showed complications including bullous keratopathy, early- and late-onset glaucoma, and late-onset pupil deformity.²⁶ In a study comparing open-loop AC IOLs and PC IOLs in primary and secondary implantation, the relationship between the haptics and surrounding tissues examined by ultrasound biomicroscopy revealed negative long-term effects of AC IOLs as open-loop haptics can penetrate through the iris into the ciliary body, risking uveitis and glaucoma.²⁷

Advantages of repositioning existing dislocated PC IOLs rather than performing a lens exchange are the

absence of a large limbal incision, providing a stable operative environment; less uncontrolled egress of fluid through the large limbal wound; and less corneal endothelial damage than that caused by removing 1 IOL and then implanting a replacement lens. In our series of IOL repositioning, mild transient corneal striae were present in 50% of eyes; however, no eye developed persistent corneal edema over a median follow-up of 15 months.

In our study, visual acuity was maintained or improved in 12 of 14 eyes. There were no major complications attributable to haptic externalization through a clear corneal incision, such as intraoperative iris trauma, persistent corneal edema, or bullous keratopathy. Potential complications of transscleral fixation of PC IOLs include suture erosion, endophthalmitis, vitreous hemorrhage, retinal detachment, CME, glaucoma, and recurrent dislocation caused by a broken suture.² Partial-thickness scleral flaps, used in our series, may prevent suture knot exposure and reduce the risk for late-onset endophthalmitis.²⁸ There were no cases of knot exposure or endophthalmitis in our series. Two eyes (14%) developed mild vitreous hemorrhage, which resolved spontaneously within 1 week. One eye (7%) developed CME, which reduced visual acuity but was associated with the use of latanoprost to treat preexisting glaucoma. Latanoprost may worsen CME, especially after previous vitrectomy.²⁹

In conclusion, this technique simplifies scleral fixation of dislocated PC IOLs and allows for successful repositioning of dislocated and subluxated PC IOLs. It also minimizes intraoperative maneuvers and reduces the risks for intraoperative trauma. It allows secure suture placement around the haptic in the externalized position, minimizing slippage or late redislocation. Although this technique requires an additional small corneal incision and the PC IOL must be brought into the anterior chamber, there is no significant increase in corneal or iris complications. Because ours was a small retrospective surgical series, it is not possible to compare our results with those of cases in which the dislocated PC IOL was managed with vitrectomy and exchange for an AC IOL. Larger randomized studies with longer follow-up that directly compare IOL repositioning and exchange have not been reported. However, our study shows that scleral fixation of dislocated PC IOLs using temporary haptic externalization through a clear corneal

incision minimizes the need for complicated intraocular maneuvers, has a low incidence of complications, and yields good visual outcomes, making it an effective option in the management of dislocated PC IOLs.

References

- Mello MO Jr, Scott IU, Smiddy WE, et al. Surgical management and outcomes of dislocated intraocular lenses. *Ophthalmology* 2000; 107:62–67
- Chan CK, Agarwal A, Agarwal S, Agarwal A. Management of dislocated intraocular implants. *Ophthalmol Clin North Am* 2001; 14(4):681–693
- Smiddy WE, Ibanez GV, Alfonso E, Flynn HW Jr. Surgical management of dislocated intraocular lenses. *J Cataract Refract Surg* 1995; 21:64–69
- Chan CK. An improved technique for management of dislocated posterior chamber implants. *Ophthalmology* 1992; 99:51–57
- Kokame GT, Atebara NH, Bennett MD. Modified technique of haptic externalization for scleral fixation of dislocated posterior chamber lens implants. *Am J Ophthalmol* 2001; 131:129–131
- Thach AB, Dugel PU, Sipperley JO, et al. Outcome of sulcus fixation of dislocated posterior chamber intraocular lenses using temporary externalization of the haptics. *Ophthalmology* 2000; 107:480–484
- Mittra RA, Connor TB, Han DP, et al. Removal of dislocated intraocular lenses using pars plana vitrectomy with placement of an open-loop, flexible anterior chamber lens. *Ophthalmology* 1998; 105:1011–1014
- Sarrafzadeh R, Ruby AJ, Hassan TS, et al. A comparison of visual results and complications in eyes with posterior chamber intraocular lens dislocation treated with pars plana vitrectomy and lens repositioning or lens exchange. *Ophthalmology* 2001; 108:82–89
- Bloom SM, Wyszynski RE, Brucker AJ. Scleral fixation suture for dislocated posterior chamber intraocular lens. *Ophthalmic Surg* 1990; 21:851–854
- Campo RV, Chung KD, Oyakawa RT. Pars plana vitrectomy in the management of dislocated posterior chamber lenses. *Am J Ophthalmol* 1989; 108:529–534
- Akduman L. Transscleral fixation of a dislocated silicone plate haptic intraocular lens via the pars plana. *Ophthalmic Surg Lasers* 1998; 29:519–521
- Azar DT, Wiley WF. Double-knot transscleral suture fixation technique for displaced intraocular lenses. *Am J Ophthalmol* 1999; 128:644–646
- Koh HJ, Kim CY, Lim SJ, Kwon OW. Scleral fixation technique using 2 corneal tunnels for a dislocated intraocular lens. *J Cataract Refract Surg* 2000; 26:1439–1441
- Kwok AKH, Cheng ACK, Lam DSC. Surgical technique for transcleral-fixation of a dislocated posterior chamber intraocular lens. *Am J Ophthalmol* 2001; 132:406–408
- Smiddy WE, Flynn HW Jr. Needle-assisted scleral fixation suture technique for relocating posteriorly dislocated IOLs [letter]. *Arch Ophthalmol* 1993; 111:161–162
- Smiddy WE. Modification of scleral suture fixation technique for dislocated posterior chamber intraocular lens implants [letter]. *Arch Ophthalmol* 1998; 116:967
- Maguire AM, Blumenkranz MS, Ward TG, Winkelman JZ. Scleral loop fixation for posteriorly dislocated intraocular lenses; operative technique and long-term results. *Arch Ophthalmol* 1991; 109:1754–1758
- Lawrence FC II, Hubbard WA. “Lens lasso” repositioning of dislocated posterior chamber intraocular lenses. *Retina* 1994; 14:47–50
- Navia-Aray EA. A technique for knotting a suture around the loops of a dislocated intraocular lens, within the eye, for fixation in the ciliary sulcus. *Ophthalmic Surg* 1993; 24:702–707
- Lee S-C, Tseng S-H, Cheng H-C, Chen FK. Slipknot for scleral fixation of intraocular lenses. *J Cataract Refract Surg* 2001; 27:662–664
- Virata SR, Holekamp NM, Meredith TA. “Luggage-tag” suture fixation of partially dislocated intraocular lenses. *Ophthalmic Surg Lasers* 2001; 32:346–348
- Hanemoto T, Ideta H, Kawasaki T. Dislocated intraocular lens fixation using intraocular cowhitch knot. *Am J Ophthalmol* 2001; 131:265–267
- Hu BV, Shin DH, Gibbs KA, Hong YJ. Implantation of posterior chamber lens in the absence of capsular and zonular support. *Arch Ophthalmol* 1988; 106:416–420
- Dick HB, Augustin AJ. Lens implant selection with absence of capsular support. *Curr Opin Ophthalmol* 2001; 12:47–57
- Johnston RL, Charteris DG. Pars plana vitrectomy and sutured posterior chamber lens implantation. *Curr Opin Ophthalmol* 2001; 12:216–221
- Sawada T, Kimura W, Kimura T, et al. Long-term follow-up of primary anterior chamber intraocular lens implantation. *J Cataract Refract Surg* 1998; 24:1515–1520
- Chen W, Liu Y, Wang N, et al. Comparison of the effects of two types of intraocular lens. *Chin Med J* 2001; 114:1286–1289
- Heilskov T, Joondeph BC, Olsen KR, Blankenship GW. Late endophthalmitis after transscleral fixation of a posterior chamber intraocular lens. *Arch Ophthalmol* 1989; 107:1427
- Yeh PC, Ramanathan S. Latanoprost and clinically significant cystoid macular edema after uneventful phacoemulsification with intraocular lens implantation. *J Cataract Refract Surg* 2002; 28:1814–1818