

## Chapter 1

# Update on Advances in Polypoidal Choroidal Vasculopathy - A Subtype of Subretinal Neovascularization

Gregg T Kokame<sup>1-5</sup>, Elyse S Tom<sup>5</sup> and Jessica G Shantha<sup>2-4</sup>

<sup>1</sup>Division of Ophthalmology, Department of Surgery, University of Hawaii School of Medicine, USA

<sup>2</sup>The Retina Center at Pali Momi, USA

<sup>3</sup>Retina Consultants of Hawaii, USA

<sup>4</sup>Hawaii Macula and Retina Institute, USA

<sup>5</sup>John A. Burns School of Medicine, University of Hawaii School of Medicine, USA

**\*Corresponding Author:** Gregg T Kokame, Hawaii Macula and Retina Institute, 98-1079 Moanalua Road, Suite 470, Aiea, Hawaii, 96701, USA; Tel: 1-808-4878928; Fax: 1-808-4873699; Email: retinahi@aol.com

First Published **September 08, 2016**

Copyright: © 2016 Gregg T Kokame, Elyse S Tom and Jessica G Shantha.

*This article is distributed under the terms of the Creative Commons Attribution 4.0 International License (<http://creativecommons.org/licenses/by/4.0/>), which permits unrestricted use, distribution, and reproduction in any medium, provided you give appropriate credit to the original author(s) and the source.*

## Abstract

Polypoidal choroidal vasculopathy (PCV) is a subtype of subretinal neovascularization and a variant of age-related macular degeneration. Recent advances in diagnosis and treatment of this disease entity have improved the management of PCV and its outcomes. The diagnosis of PCV is often made based on funduscopic findings, but more definitively on indocyanine green angiography (ICGA) patterns. OCT, OCT-A and en face OCT offer alternative ways to diagnose PCV if ICG angiography is not available. The treatment of PCV is controversial but options include photodynamic therapy (PDT), anti-vascular endothelial growth factor (anti-VEGF) therapy, and laser photocoagulation. Anti-VEGF therapy is an important therapeutic option for PCV, but alternative treatment may be needed with resistance to injections. While PDT results in greater closure of the PCV complex and polyp regression, anti-VEGF therapy has been shown to have signifi-

cant inhibition of exudation and leakage with in general less closure of the PCV complex itself.

## Introduction

Polypoidal choroidal vasculopathy (PCV) results in serosanguinous maculopathy and is a variant of neovascular age-related macular degeneration (NVAMD) [1]. Wet age-related macular degeneration (AMD) is the leading cause of irreversible blindness in the developed world [2]. Many of the clinical findings in PCV are indistinguishable from subretinal neovascularization associated with AMD [3]. However, it is important to make the distinction between PCV and typical neovascular AMD as the epidemiology, clinical characteristics, natural history and treatment approach differs.

PCV presents with subretinal hemorrhage, retinal pigment epithelial detachment (RPED), and subretinal fluid associated with a subretinal network of abnormal branching vessels with characteristic terminal aneurysmal dilations or “polyp-like” structures [4,5]. The reddish-orange polypoid structures of PCV were originally thought to be a vascular anomaly of the choroid, but histopathologic studies have shown conflicting findings on whether PCV is a choroidal vascular abnormality or type of subretinal neovascularization [3]. Recently, PCV has been defined as a type 1 choroidal neovascularization (CNV) with or without a branching vascular network (BVN) and with polypoidal dilated vessels located between the retinal pigment epithelium (RPE) and Bruch membrane [3].

PCV is gaining increased recognition globally as a cause of exudative and hemorrhagic complications in the macula [3]. It is reported that 50% of patients with PCV progress to suffer from severe visual acuity loss secondary to recurrent periods of hemorrhage, exudation and scarring [6,7]. PCV is more common in Asian countries, as up to 50% of patients with macular exudation and hemorrhage have PCV [8]. Nevertheless, PCV is not uncommon in nations with higher Caucasian populations (20% or higher). A recent Brazilian study, in which most of the patients with neovascular AMD were of European descent showed that 24.5% had PCV based on indocyanine green angiography (ICGA) at initial diagnosis [9]. A Swiss study of neovascular AMD refractory to ranibizumab treatment reported that 21.5% of patients had the PCV variant, not neovascular AMD [10].

PCV has a remarkably varied clinical presentation among different ethnic populations. In Asian populations, it is much more common in males and more commonly presents unilaterally and in the macula [11]. However, in white and black patients, it is more common in women and often found bilaterally and in the peripapillary areas [12]. This difference may result in a worse prognosis in Asians due to the macular location being more likely to affect central vision [3]. The etiology for these differences is unknown but continues to be a regular clinical observation.

## Imaging PCV for Diagnosis

The diagnosis of PCV is often made based on characteristic fundusoscopic findings and indocyanine green angiography (ICGA) patterns. ICGA is the gold standard for the imaging and diagnosis of PCV, in which there are polypoidal aneurismal dilations with or without a BVN. The relative infrequent use of ICGA in some clinical practices contributes significantly to the under diagnosis of this disease entity. Therefore, it is imperative to understand the imaging features of PCV on the available diagnostic tools that are commonly utilized in clinical practices. Herein we will review the distinguishing characteristics of PCV on exam and various diagnostic modalities.

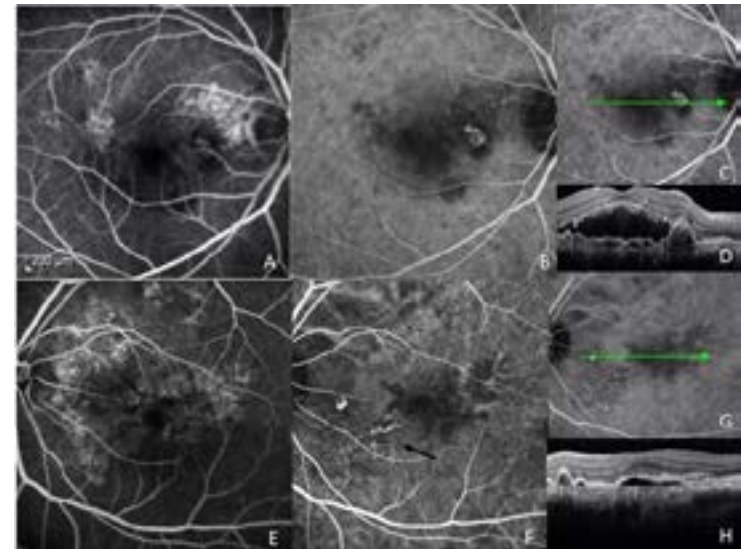
## Fundus Examination

On fundus examination, PCV presents with subretinal fluid and subretinal hemorrhage or hemorrhagic pigment epithelial detachment (PED), which is often indistinguishable from neovascular AMD. Occasionally, characteristic reddish-orange, subretinal, polypoidal lesions may be easily seen [1]. Nevertheless, the only definitive diagnostic test for PCV is ICGA [13,14].

## ICG Angiography

ICGA is the definitive method for the diagnosis of PCV [15,16]. On ICGA, PCV is seen as an abnormal subretinal vascular complex, with aneurismal dilations or polyps and often with aBVN. The polyps appear as nodular hyperfluorescence most characteristically with a hypo-

fluorescent halo and rarely as a pulsatile lesion. PCV is often under diagnosed in the United States, as ICGA is not routinely done in the initial evaluation for serosanguinous maculopathy [17]. ICGA is essential for PCV diagnosis, but since it is not always available, clinicians must use alternative imaging techniques such as optical coherence tomography (OCT), en face OCT and OCT-angiography to help to make the diagnosis of PCV (Figure 1).



**Figure 1:** An Asian male with treatment naive bilateral polypoidal choroidal vasculopathy. Fluorescein angiography (FA) of the right eye (A) with corresponding indocyanine angiography (ICGA, B) displays characteristic polyp with surrounding hypofluorescent halo. Optical coherence tomography and line scan (C,D) shows polyp lesion with subretinal fluid and branching vascular network. The left eye FA and corresponding ICGA (E,F). ICGA better visualizes the characteristic hyperfluorescent polyp with BVN (arrow). Line scan and OCT (G,H) shows polyp and a retinal pigment epithelial detachment.

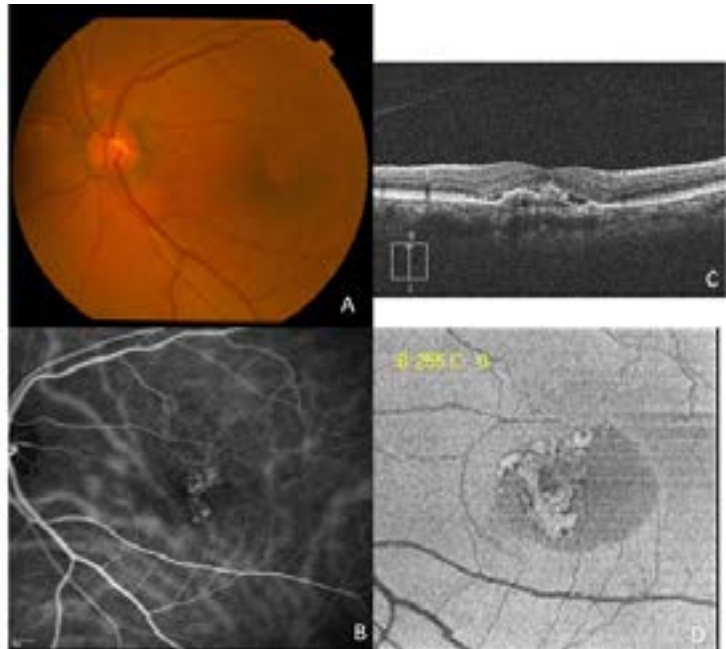
## OCT

Current technology allows OCT to precisely localize PCV lesions that have been identified with ICGA [3]. On OCT, the PCV polyps appear as a focal, steep-sloped, highly peaked elevation of the RPE (an elevation similar to an inverted “U” shape). There are often associated serous retinal detachments. The BVN characteristically appears as a shallow, more diffuse elevation of the RPE, or two hyperreflective lines that is termed the double-layer sign [18-20]. Distinguishing features on OCT that also are more often seen in PCV than NVAMD include increased frequency of serous retinal detachment, increased height of the serous retinal detachment, less intraretinal edema and thicker choroid [18,21,22]. A recent Korean retrospective case series involving 263 eyes reported that the OCT-based diagnosis of PCV has a high sensitivity (85.7%) and specificity (86.2%), suggesting that PCV can be diagnosed by characteristic findings on OCT. Furthermore, the study found that the short-term treatment outcomes between PCV cases that were classified based on ICGA and those using OCT were comparable, further suggesting that OCT may be a useful alternative method to ICG for the diagnosis of PCV [23]. Using both ICGA and OCT with point-to-point localization of the PCV lesions may confirm the diagnosis of PCV due to the ability to visualize the corresponding elevation of the RPE to the hyperfluorescent lesions shown on ICGA [3]. With treatment, especially after photodynamic therapy (PDT) but

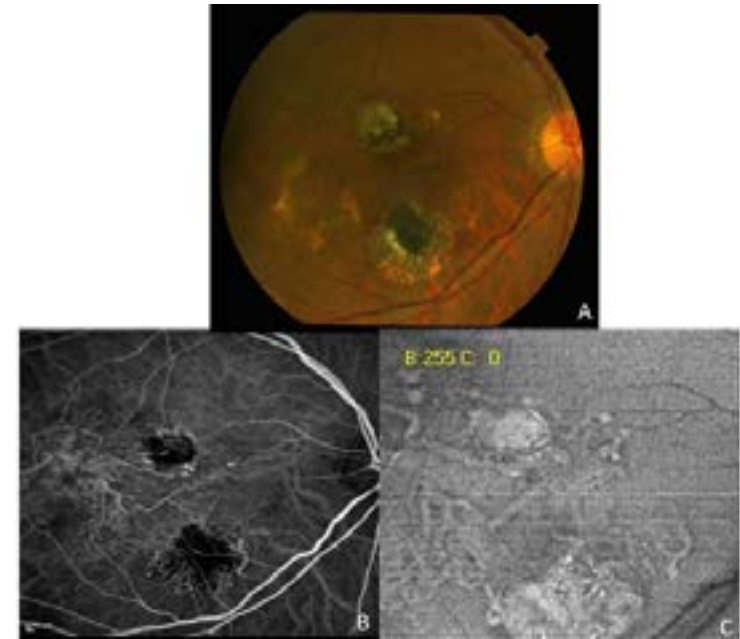
also after antiangiogenic therapy, the polypoidal lesions may not be visible, but the BVN usually persists on imaging [3]. This persistence of the BVN with resolution of polyps after treatment is important to understand in the evaluation and diagnosis of PCV lesions after treatment has already been initiated.

## En Face OCT

En Face OCT is an additional easy, noninvasive method of imaging PCV complexes (Figure 2 and Figure 3). It is available as a software viewing option on most spectral-domain OCT devices. En face OCT creates two-dimensional images from a 3D volume while allowing for topographical analysis and assessment of the lesions extent [24]. When imaging the PCV complex, it is best to scan below the RPE and above Bruch membrane using slabs of 10  $\mu\text{m}$  to 30  $\mu\text{m}$  [25]. The PCV complexes appear as dilated vascular structures with hyperechogenic borders. They may appear larger with en face imaging due to the ability to detect areas that may have no flow and due to the imaging of tissue draped over and around the PCV vessels. En face OCT allows for visualization of the choroidal vascular network at a given depth but is unable to reveal the entire BVN in most cases [24]. Studies have shown that both en face OCT and ICGA are similar in their ability to identify PCV complexes [25-30].



**Figure 2:** An Asian female with previous anti-VEGF and PDT therapy in the left eye. Color fundus photo (A) and ICGA (B) with poor visualization of the PCV complex. Line scan OCT (C) shows a type I CNV with subretinal fluid. En-face OCT image (D) displays better visualization of the PCV complex.



**Figure 3:** A Filipino-Asian female with polypoidal choroidal vasculopathy in the right eye previously treated with macular laser suggests a large polypoidal complex in central and temporal macula of the right eye. A. Note superior and inferior RPE scars from prior macular laser of leaking polyps in fundus photo B. ICGA showing large branching vascular network and nasal polyp C. En face OCT showing characteristic PCV complex in greater detail and extent than ICGA.

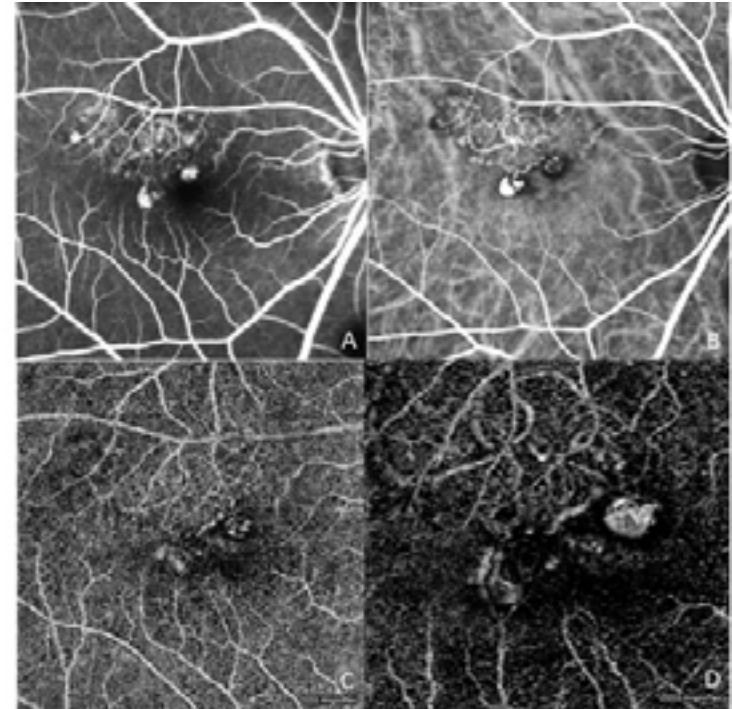
## OCT-Angiography

Imaging modalities for diseases of the retina are changing due to advances in technology and diagnostic innovations. OCT-angiography (OCT-A) is a new non-



invasive technique that allows imaging of blood flow through the retinal and choroidal microvasculature. The advantages of OCT-A over traditional ICGA and FA are that it is noninvasive, requires no injection of contrast dye, and has a rapid acquisition time. The disadvantage of OCT-A is that it is not yet widely available due to its recent introduction into the marketplace. Its validity in identifying the complete PCV complex is still under investigation, but preliminary studies with existing technology show that it can image blood flow in some PCV complexes, but the polyp is less well visualized than the BVN. The PCV complex is incompletely imaged compared to ICGA. As this technology continues to change and we learn more about the imaging features in different retinal diseases it has promise in becoming a useful diagnostic tool for PCV.

A recent study described the OCT-A findings of the branching vascular network in PCV as a hyperflow lesion and the polyp lesions as a hypo-flow round structure in most cases. However, the polyp can also appear as a hyperflow round structure surrounded by a hypo-intense halo in some cases similar to ICGA. The polyp usually appears as a hypo-intense round structure likely because of low turbulent blood flow inside of the polyp, in contrast to the BVN [31] (Figure 4). OCT-A has been shown to offer anatomical information that is comparable to ICGA in some cases. But it is not yet a replacement for ICGA [32]. Further studies and future development in software will allow improved definition of PCV lesions on OCT-A [31,33].



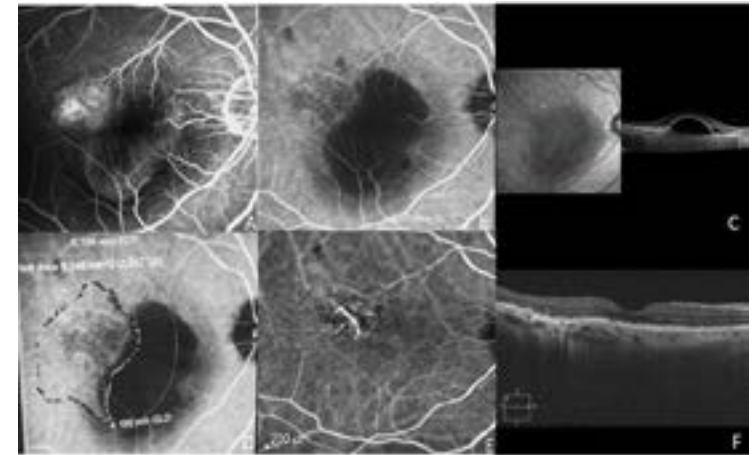
**Figure 4:** An Asian female with PCV in the right eye and previous anti-VEGF therapy. A. Fluorescein angiogram showing focal areas of leakage but poor vascular details. B. ICGA displays excellent vascular detail of branching vascular network and polyps. C. OCT angiography 6X6 scan and 3X3 scan (D) showing some flow in regions between RPE and Bruch's membrane, but poor vascular detail compared to the ICG.

## Treatment of PCV

Treatment of PCV is complex and remains controversial as therapy depends on visual acuity, location of the PCV complex and response to therapy. Treatment options include PDT, anti-vascular endothelial growth factor (anti-VEGF) therapy and laser photocoagulation.

### Photodynamic Therapy

PDT has been the mainstay of treatment in Asia for many years. It has been shown to cause closure of the vascular lesions and resolution of the serous and hemorrhagic complications of PCV [3]. The multicenter, randomized EVEREST clinical trial, which compared PDT alone, anti-VEGF therapy (monthly intravitreal ranibizumab) alone and PDT combined with anti-VEGF therapy over 6 months, is one of the landmark studies in PCV treatment. This study found that while the visual results were not statistically significant among the groups, polyp regression was greatest with PDT combined with ranibizumab (Lucentis, Genentech), followed by PDT alone and then ranibizumab alone, with polyp closure rates of 77.8%, 71.4% and 28.6%, respectively [34]. This study also suggested that visual results do not necessarily correlate with the anatomic changes in response to treatment. Another recent study that compared 3-year visual outcomes after ranibizumab therapy alone and in combination with PDT found that improvement in visual acuity after combination therapy was significantly better than after ranibizumab monotherapy [35].



**Figure 5:** PCV presenting with a vascularized RPED in an Asian male patient with initial visual acuity of 20/60. A. Fluorescein angiogram showing RPED with superotemporal occult leakage. B. ICG angiogram showing superotemporal PCV network. Note the dark hypofluorescent area corresponding to the RPED on the scanning laser ophthalmoscopic image. C. Corresponding OCT showing RPED and nasal serous detachment. D. The region of the visible PCV complex was mapped and the size of PDT treatment was the greatest linear dimension with an additional 300  $\mu$ m border. E. Post-treatment ICG showing resolution of the PCV complex and the RPED and corresponding OCT (F) confirming resolution of the RPED and serous detachment. Visual acuity was 20/30 at 32 months following one PDT treatment and 3 subsequent intravitreal bevacizumab and dexamethasone injections. No treatment has been necessary for over 2 years.

An expert panel on PCV treatment concluded that in subfoveal and juxtafoveal PCV, PDT alone or in combination with anti-VEGF should be first-line treatment [36]. However, PDT is often not used in eyes with subfoveal

lesions with good visual acuity of 20/40 or better due to the rare complications of choroidal ischemia or subretinal hemorrhage. Anti-VEGF therapy alone can reduce the risk of choroidal ischemia or subretinal hemorrhage, while decreasing leaking and bleeding from the PCV complex, but it has more limited efficacy in regression of the PCV complex than PDT (Figure 5).

### Anti-VEGF Therapy

While PDT has been the mainstay therapy for PCV in Asia, anti-VEGF therapy is more often initially utilized in the United States and Europe, particularly for serous and hemorrhagic complications in the macula. However, since the funduscopic findings in PCV and wet AMD are often indistinguishable, and ICGA is not always performed in clinical practice, some of these patients actually have PCV but are not diagnosed [37]. This is problematic because PCV has a higher resistance to anti-VEGF therapy [10, 38, 39]. In fact, one study reported that PCV may even progress in eyes already receiving antiangiogenic therapy [38]. Antiangiogenic therapy usually decreases leakage and bleeding in PCV, but the visual results have a poorer response compared to those seen in the exudative AMD studies. Retrospective studies with bevacizumab (Avastin, Genetech) show a low rate of polyp closure (21%) but some improvement in visual acuity and anatomic changes in the retina [40].

In the PEARL 1 study, a prospective, open-label clinical trial of monthly ranibizumab, PCV complexes were

decreased in 38%, stable in 31%, and increased in 31% of patients at 1 year. There was good resolution of leakage and bleeding and a 23% chance of significant visual improvement in this cohort of 13 eyes. This statistically significant improvement in visual acuity and a decrease in central foveal thickness indicates that antiangiogenic treatment is a worthwhile option even though anatomic changes such as regression of the PCV complex was seen in only 38% of PCV complexes at 1 year [41]. PDT has a better rate of anatomic PCV closure compared to ranibizumab, but anatomic regression may not be needed for vision recovery since the natural history of PCV includes a 50% chance of stable vision [7]. The importance of regression of the PCV complex for vision recovery and long-term prognosis is still uncertain.

In the LAPTOP study, a prospective, multicenter randomized clinical trial that compared PDT and ranibizumab, visual acuity outcomes at 1 year were superior in the ranibizumab treatment group compared to PDT [42]. This was the first trial to show superior visual results with ranibizumab when compared with PDT. In the ranibizumab group, 30.4% of patients showed visual improvement compared to 17% in the PDT treatment group [42]. The difference in treatment results between the EVEREST study and the LAPTOP study may have occurred due to different polypoidal entry criteria and different patient populations, but this supports the concept that antiangiogenic therapy is a reasonable treatment approach, al-



though resistance may occur more frequently in PCV [43].

The PEARL 2 trial studied high-dose (2.0 mg) ranibizumab therapy prospectively in 19 eyes with active leakage or bleeding from PCV. While the higher dose did not result in more significant resolution of edema or subretinal fluid, high-dose ranibizumab showed a much higher rate of polyp regression compared to standard dose of ranibizumab. Polyps decreased in 78.9% of eyes on the higher dose of ranibizumab and were stable in 21.1% of eyes [3]. Since the PCV vessels are located under the RPE but above Bruch's membrane, a higher dose of medication may be needed to penetrate into the sub-RPE space through an intact RPE or to overcome anti-VEGF resistance [3]. Visual results were similar to the responses seen in the PDT subgroups in the EVEREST study, as 26% of patients had statistically significant improvement in visual acuity at 6 months.

A recent retrospective study in Japan that evaluated the responsiveness to ranibizumab monotherapy based on the presence of single or multiple polyps found that the multiple polyps group had poorer improvement in visual acuity compared to the single polyp group at 2 years. In addition, the mean CRT in both groups after 3 months of treatment was decreased, suggesting some benefit from the ranibizumab [43].

Both ranibizumab and bevacizumab have been studied as anti-VEGF therapies for the treatment of PCV. Current studies have shown decreased exudation and macular edema with bevacizumab, but its effectiveness has been

reported to decrease during the second year of therapy, suggesting the possible development of resistance for bevacizumab [44]. One study retrospectively compared the 6-month results of eyes treated with either ranibizumab or bevacizumab and found no difference in number of injections, improvement in vision, or decrease in mean central foveal thickness between the two treatment groups [40].

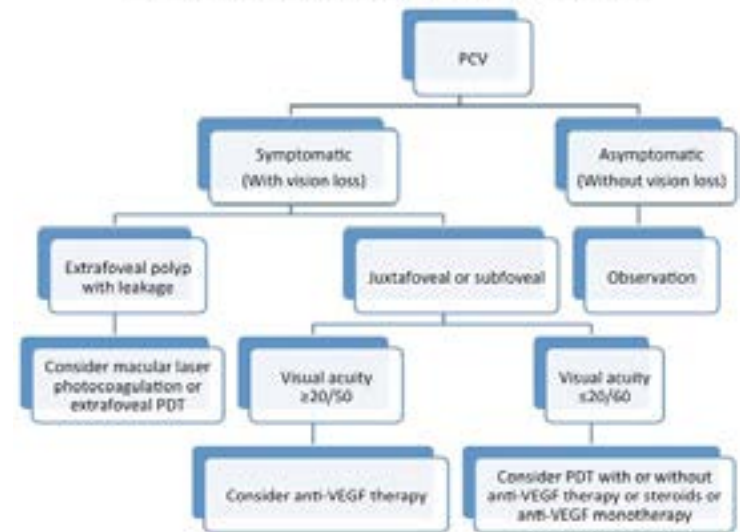
Aflibercept (Eylea, Regeneron), an anti-VEGF agent, is also used to treat PCV. A 1-year retrospective review of patients with treatment-naïve PCV showed significant improvement in vision, decreased central foveal thickness, and PCV regression in 66% of patients at 3 months [45]. Twenty-six percent of those patients with complete polyp regression at 3 months showed recurrence at one year, which indicates that polypoidal lesions must be observed regularly, even in eyes where lesions regressed. This finding also emphasizes the complexity of PCV management. In another retrospective case series that compared effectiveness of aflibercept to ranibizumab, polyp regression was significantly more frequent in the aflibercept treatment group (39.5%) than in the ranibizumab group (21.6%), but visual acuity improvement did not differ significantly [46]. Furthermore, two recent retrospective studies reported that in eyes refractory to ranibizumab therapy, switching to aflibercept injections decreased the choroidal thickness, reduced exudative lesions and either maintained or improved visual acuity over 6 months [47,48].

Anti-VEGF therapy is less effective for treatment of PCV than for neovascular AMD due to a higher incidence of anti-VEGF resistance. In patients who were initially diagnosed with neovascular AMD but were resistant to anti-VEGF therapy, ICGA eventually revealed a PCV diagnosis, which led to the use of PDT treatment. This PDT treatment lessened the burden of intravitreal injections while improving anatomic and visual outcomes [38,49].

### Laser Photocoagulation

Laser photocoagulation is used to treat extra foveal polyps associated with subretinal hemorrhage and subretinal fluid. It has been shown to decrease exudation with regression of polypoidal lesions and improvement in visual acuity, which can result in long-term resolution of polyps that are safely away from the fovea. However, in the majority of cases, the polyps and the branching vascular network complex leak. It cannot be used for cases where the lesion extends too close to the fovea or through the fovea due to potential underlying damage to the retina and RPE, which may lead to irreversible visual acuity loss [50].

### Proposed Treatment Algorithm for PCV



**Figure 6:** Treatment Algorithm for PCV.

The first step in the therapeutic decision making process requires determining whether the patient is symptomatic or asymptomatic. If asymptomatic, observation is recommended. If the patient is symptomatic (with vision loss) and an extrafoveal polyp with leakage is seen, consider macular laser photocoagulation or PDT can be considered for a broader extrafoveal leaking PCV complex. If symptomatic and the polyp is juxtafoveal or subfoveal, treatment depends on visual acuity. If visual acuity is 20/50 or better, consider anti-VEGF therapy, and PDT is not usually recommended due to adverse events. If visual acuity is 20/60 or worse, consider PDT with or without anti-VEGF therapy and steroids, or anti-VEGF therapy depending on patient factors, such as easy access to doctor, travel, mobility and other factors, which affect a patient's ability to meet the treatment burden of frequent injections.

## Conclusion

Improving the diagnosis of PCV is made possible by new diagnostic technology but also remains a challenge as the disease has to be defined on different imaging modalities and has to be translated to using these diagnostic tests in clinical practice. New technology to diagnose PCV includes en face OCT and OCT-A. Once the barriers are overcome, treatment with PDT must be considered. The treatment paradigm for PCV involves both PDT and anti-VEGF therapy. Each case is unique and needs careful consideration. Treatment depends on various factors including 1) location of polyps and the BVN, 2) degree of leakage, 3) initial visual acuity and 4) response to anti-VEGF therapy. Treating PCV is different from treating neovascular AMD as the response to PDT or anti-VEGF therapy varies. Since PCV is a subtype of type I subretinal neovascularization located beneath the RPE, antiangiogenic therapy is an important therapeutic option, but alternative therapy may be necessary with resistance to injections. While PDT shows greater anatomic closure of the PCV complex and polyp regression, anti-VEGF therapy has been shown to have good visual improvement without the uncommon but significant risks of vision loss from choroidal ischemia or subretinal hemorrhage. It is still unknown whether polyp closure in PCV has a significant effect on long term visual outcome in the management of polypoidal choroidal vasculopathy.

PCV is gaining recognition globally as methods of diagnosis and treatment for this disease become more available and there is increasing awareness of this disease entity. The diagnosis and appropriate management of PCV depends on various factors including 1) availability and expertise in the reading of ICGA, 2) access to PDT lasers and 3) personnel needed to perform the ICGA and PDT. OCT, OCT-A and en face OCT offer alternative ways to diagnose PCV if ICG angiography is not accessible. With the use of these diagnostic modalities, awareness of the disease will increase, which may improve treatment outcomes and decrease treatment burden in PCV patients. Presently, en face OCT is the most promising and widely available diagnostic entity to possibly allow PCV diagnosis without ICGA [30].

## Acknowledgement

**Conflicts of Interest and Sources of Funding:** The authors have not received grant support or research funding for this study. The authors do not have any proprietary interests in the materials described.

## References

1. Honda S, Matsumiya W, Negi A. Polypoidal choroidal vasculopathy: clinical features and genetic predisposition. *Ophthalmologica*. 2014; 231: 59-74.
2. Bressler NM. Age-related macular degeneration is the leading cause of blindness... *JAMA*. 2004; 291: 1900-1901.
3. Kokame GT. Prospective evaluation of subretinal vessel location in polypoidal choroidal vasculopathy (PCV) and response of hemorrhagic and exudative PCV to high-dose antiangiogenic therapy (an American Ophthalmological Society thesis). *Trans Am Ophthalmol Soc*. 2014; 112: 74-93.
4. Imamura Y, Engelbert M, Iida T, Freund KB, Yannuzzi LA, et al. Polypoidal choroidal vasculopathy: a review. *Surv Ophthalmol*. 2010; 55: 501-515.
5. Yannuzzi LA, Sorensen J, Spaide RF, Lipson B. Idiopathic polypoidal choroidal vasculopathy. *Retina*. 1990; 10: 1-8.
6. Cheung CM, Yang E, Lee WK, Lee GK, Mathur R, et al. The natural history of polypoidal choroidal vasculopathy: a multi-center series of untreated Asian patients. *Graefes Arch Clin Exp Ophthalmol*. 2015; 253: 2075-2085.
7. Uyama M, Wada M, Nagai Y, Matsubara T, Matsunaga H, et al. Polypoidal choroidal vasculopathy: natural history. *Am J Ophthalmol*. 2002; 133: 639-648.
8. Ciardella AP, Donsoff IM, Huang SJ, Costa DL, Yannuzzi LA, et al. Polypoidal choroidal vasculopathy. *Surv Ophthalmol*. 2004; 49: 25-37.
9. Pereira FB, Veloso CE, Kokame GT, Nehemy MB. Characteristics of Neovascular Age-Related Macular Degeneration in Brazilian Patients. *Ophthalmologica*. 2015; 234: 233-242.
10. Hatz K, Prunte C. Polypoidal choroidal vasculopathy in Caucasian patients with presumed neovascular age-related macular degeneration and poor ranibizumab response. *Br J Ophthalmol*. 2014; 98: 188-194.
11. Honda S, matsumiya W, Negi A. Polypoidal choroidal vasculopathy: clinical features and genetic predisposition. *Ophthalmologica*. 2014; 231: 59-74.
12. Lafaut BA, Leys AM, Snyers B, Rasquin F, De Laey JJ, et al. Polypoidal choroidal vasculopathy in Caucasians. *Graefes Arch Clin Exp Ophthalmol*. 2000; 238: 752-759.
13. Khan S, Englebert M, Imamura Y, Freund KB. Polypoidal choroidal vasculopathy. Simultaneous

- indocyanine green angiography and eye-tracked spectral domain optical coherence tomography findings. *Retina*. 2012; 32: 1057-1068.
14. Kokame GT. Polypoidal choroidal vasculopathy-an important diagnosis to make with therapeutic implications. *Retina*. 2012; 32: 1446-1448.
  15. Tan CS, Ngo WK, Chen JP, Tan NW, Lim TH, et al. EVEREST study group. EVEREST study report 2: imaging and grading protocol, and baseline characteristics of a randomized controlled trial of polypoidal choroidal vasculopathy. *Br J Ophthalmol*. 2015; 99: 624-628.
  16. Spaide RF, Yannuzzi LA, Slakter JS, Sorenson J, Orlach DA, et al. Indocyanine green videoangiography of idiopathic polypoidal choroidal vasculopathy. *Retina*. 1995; 15: 100-110.
  17. Kokame GT. Polypoidal choroidal vasculopathy-an important diagnosis to make with therapeutic implications. *Retina*. 2012; 32: 1446-1448.
  18. Ozawa S, Ishikawa K, Ito Y, Nishihara H, Yamakoshi T, et al. Differences in macular morphology between polypoidal choroidal vasculopathy and exudative age-related macular degeneration detected by optical coherence tomography. *Retina*. 2009; 29: 793-802.
  19. Iijima H, Iida T, Imai M, Gohdo T, Tsukahara S, et al. Optical coherence tomography of orange-red subretinal lesions in eyes with idiopathic polypoidal choroidal vasculopathy. *Am J Ophthalmol*. 2000; 129: 21-26.
  20. Sato T, Kishi S, Watanabe G, Matsumoto H, Mukai R, et al. Tomographic features of branching vascular networks in polypoidal choroidal vasculopathy. *Retina*. 2007; 27: 589-594.
  21. Liu R, Li J, Li Z, Yu S, Yang Y, et al. Distinguishing polypoidal choroidal vasculopathy from typical neovascular age-related macular degeneration based on spectral domain optical coherence tomography. *Retina*. 2016; 36: 778-786.
  22. Koizumi H, Yamagishi T, Yamazaki T, Kawasaki R, Kinoshita S, et al. Subfoveal choroidal thickness in typical age-related macular degeneration and polypoidal choroidal vasculopathy. *Graefes Arch Clin Exp Ophthalmol*. 2011; 249: 1123-1128.
  23. Chang YS, Kim JH, Lee TG, Kim CG. Optical Coherence Tomography-based Diagnosis of Polypoidal choroidal Vasculopathy in Korean Patients. *Korean J Ophthalmol*. 2016; 30: 198-205.
  24. Semoun O, Coscas F, Coscas G, Lalloum F, Srour M, et al. En face enhanced depth imaging optical coherence tomography of polypoidal choroidal vasculopathy. *Br J Ophthalmol*. 2015;.



25. Kokame GT, Hirai K, Yanagihara R. Polypoidal Choroidal Vasculopathy: Imaging by Indocyanine Green Angiography and En Face Optical Coherence Tomography. *JAMA Ophthalmol.* 2015; 133: e151886.
26. Kameda T, Tsujikawa A, Otani A, Sasahara M, Gotoh N, et al. Polypoidal choroidal vasculopathy examined with en face optical coherence tomography. *Clin Experiment Ophthalmol.* 2007; 35: 596-601.
27. Saito M, Iida T, Nagayama D. Cross-sectional and en face optical coherence tomographic features of polypoidal choroidal vasculopathy. *Retina.* 2008; 28: 459-464.
28. Sayanagi K, Gomi F, Akiba M, Sawa M, Hara C, et al. En-face high-penetration optical coherence tomography imaging in polypoidal choroidal vasculopathy. *Br J Ophthalmol.* 2015; 99: 29-35.
29. Alasil T, Ferrara D, Adhi M, Brewer E, Kraus MF, et al. En face imaging of the choroid in polypoidal choroidal vasculopathy using swept-source optical coherence tomography. *Am J Ophthalmol.* 2015; 159: 634-643.
30. Kokame GT, Shantha JG, Hirai K, Ayabe J. En-Face Spectral Domain Optical Coherence Tomography for the Diagnosis and Evaluation of Polypoidal Choroidal Vasculopathy. In Press, *OSLI Retina.* 2016.
31. Srour M, Querques G, Souied EH. Optical Coherence Tomography Angiography of Idiopathic Polypoidal Choroidal Vasculopathy. *Dev Ophthalmol.* 2016; 56: 71-76.
32. Inoue M, Balaratnasingam F, Freund KB. Optical coherence tomography angiography of polypoidal choroidal vasculopathy and polypoidal choroidal neovascularization. *Retina.* 2015; 35: 2265-2274.
33. Inoue M, Balaratnasingam C, Freund KB. Optical coherence tomography angiography of polypoidal choroidal vasculopathy and polypoidal choroidal neovascularization. *Retina.* 2015; 35: 2265-2274.
34. Koh A, Lee WK, Chen LJ, Chen SJ, Hashad Y, et al. EVEREST study: efficacy and safety of verteporfin photodynamic therapy in combination with ranibizumab or alone versus ranibizumab monotherapy in patients with symptomatic macular polypoidal choroidal vasculopathy. *Retina.* 2012; 32: 1453-1464.
35. Sakai T, Okano K, Kohno H, Tsuneoka H. Three-year visual outcomes of intravitreal ranibizumab with or without photodynamic therapy for polypoidal choroidal vasculopathy. *Acta Ophthalmol.* 2016.

36. Koh AH. Expert PCV Panel, Chen LJ, Chen SJ, Chen Y, Giridhar A. Polypoidal choroidal vasculopathy: evidence-based guidelines for clinical diagnosis and treatment. *Retina*. 2013; 33: 686-716.
37. Kleiner RC, Brucker AJ, Johnston RL. The posterior uveal bleeding syndrome. *Retina*. 1990; 10: 9-17.
38. Cho M, Barbazetto IA, Freund KB. Refractory neovascular age-related macular degeneration secondary to polypoidal choroidal vasculopathy. *Am J Ophthalmol*. 2009; 148: 70-78.
39. Stangos AN, Gandhi JS, Nair-Sahni J, Heimann H, Pournaras CJ, et al. Polypoidal choroidal vasculopathy masquerading as neovascular age-related macular degeneration refractory to ranibizumab. *Am J Ophthalmol*. 2010; 150: 666-673.
40. Cho HJ, Baek JS, Lee DW, Kim CG, Kim JW, et al. Short-term effectiveness of intravitreal bevacizumab vs. ranibizumab injections for patients with polypoidal choroidal vasculopathy. *Korean J Ophthalmol*. 2012; 26: 157-162.
41. Kokame GT, Yeung L, Teramoto K, Lai JC, Wee R, et al. Polypoidal choroidal vasculopathy exudation and hemorrhage: results of monthly ranibizumab therapy at one year. *Ophthalmologica*. 2014; 231: 94-102.
42. Oishi A, Kojima H, Mandai M, Honda S, Matsuoka T, et al. Comparison of the effect of ranibizumab and verteporfin for polypoidal choroidal vasculopathy: 12-month LAPTOP study results. *Am J Ophthalmol*. 2013; 156: 644-651.
43. Suzuki M, Nagai N, Shinoda H, Uchida A, Kurihara T, et al. Distinct Responsiveness to Intravitreal Ranibizumab Therapy in Polypoidal Choroidal Vasculopathy with Single or Multiple Polyps. *Am J Ophthalmol*. 2016; 166: 52-59.
44. Wakabayashi T, Gomi F, Sawa M, Tsujikawa M, Nishida K, et al. Intravitreal bevacizumab for exudative branching vascular networks in polypoidal choroidal vasculopathy. *Br J Ophthalmol*. 2012; 96: 394-399.
45. Hara C, Sawa M, Sayanagi K, Nishida K. One-year results of intravitreal aflibercept for polypoidal choroidal vasculopathy. *Retina*. 2016; 36: 37-45.
46. Cho HJ, Kim KM, Kim HS, Han JI, Kim CG, et al. Intravitreal Aflibercept and Ranibizumab Injections for Polypoidal Choroidal Vasculopathy. *Am J Ophthalmol*. 2016; 165: 1-6.
47. Saito M, Kano M, Itagaki K, Ise S, Imaizumi K, et al. Subfoveal choroidal thickness in polypoidal choroidal vasculopathy after switching to intravitreal aflibercept injection. *Jpn J Ophthalmol*. 2016; 60: 35-41.

48. Moon DRC, Lee DK, Kim SH, You YS, Kwon OW, et al. Aflibercept Treatment for Neovascular Age-related Macular Degeneration and Polypoidal Choroidal Vasculopathy Refractory to Anti-vascular Endothelial Growth Factor. *Korean J Ophthalmol.* 2015; 29: 226-232.
49. Hatz K, Prünke C. Polypoidal choroidal vasculopathy in Caucasian patients with presumed neovascular age-related macular degeneration and poor ranibizumab response. *Br J Ophthalmol.* 2014; 98: 188-194.
50. Lee MW, Yeo I, Wong D, Ang CL. Argon laser photocoagulation for the treatment of polypoidal choroidal vasculopathy. *Eye (Lond).* 2009; 23: 145-148.