

# INVOLUTION OF NEOVASCULAR AGE-RELATED MACULAR DEGENERATION AFTER ENDOPHTHALMITIS

Gregg T. Kokame, MD,\*†‡§¶|| Nicolas A. Yannuzzi, MD,\*\*  
Jessica G. Shantha, MD,†‡§¶†† Maya Yamane, MD,‡‡ Nidhi Relhan, MD,\*\*  
Jeffrey Gross, MD,§§ Edwin H. Ryan, MD,¶¶|| Harry W. Flynn, Jr., MD\*\*

**Purpose:** To report patients who demonstrated an alteration in the clinical and optical coherence tomography features of neovascular age-related macular degeneration after resolution of endophthalmitis.

**Methods:** Retrospective case series of the subsequent changes in the macula and need for anti-vascular endothelial growth factor therapy in patients with neovascular age-related macular degeneration who developed endophthalmitis after intravitreal injection.

**Results:** The study included seven eyes of seven patients with follow-up ranging between 3 months and 11 years. The vitreous cultures (n = 7) before intravitreal antibiotic injection were the following: culture-negative (4) and coagulase-negative Staphylococcus (3). Initial treatment included vitreous tap and injection (4) and pars plana vitrectomy (3). In 5/7 eyes, the optical coherence tomography showed resolution of subretinal fluid and serous pigment epithelial detachment, and there was no additional anti-vascular endothelial growth factor treatment administered.

**Conclusion:** After successful treatment of endophthalmitis in patients with neovascular age-related macular degeneration, there was relative involution of the maculopathy and reduced anti-vascular endothelial growth factor treatment burden in this series.

**RETINAL CASES & BRIEF REPORTS** 00:1–5, 2019

*From the \*Division of Ophthalmology, Department of Surgery, University of Hawaii School of Medicine, Honolulu, Hawaii; †The Retina Center at Pali Momi, Aiea, Hawaii; ‡Retina Consultants of Hawaii, Aiea, Hawaii; §Hawaii Macula and Retina Institute, Aiea, Hawaii; ¶John A. Burns School of Medicine, University of Hawaii School of Medicine, Honolulu, Hawaii; \*\*Department of Ophthalmology, Bascom Palmer Eye Institute, University of Miami Miller School of Medicine, Miami, Florida; ††Department of Ophthalmology, University of California San Francisco, Francis I. Proctor Foundation, San Francisco, California; ‡‡Columbia University*

*College of Physicians and Surgeons, New York, New York; §§Carolina Retina Center, Columbia, South Carolina; and ¶¶Vitreoretinal Surgery, Minneapolis, Minnesota.*

Intravitreal anti-vascular endothelial growth factor (anti-VEGF) therapy has greatly improved outcomes in neovascular age-related macular degeneration (AMD) and a number of other retinal vascular diseases. Although infrequent, a serious potential complication of intravitreal injection is endophthalmitis, estimated to occur at a rate of 0.05% or 1 in 2,000.<sup>1</sup> Outcomes are often poor, especially with cases of Streptococcus, although coagulase-negative Staphylococcus and culture-negative cases are often less virulent.<sup>2</sup> Although some eyes with neovascular AMD may respond to a finite duration of treatment, life-long therapy is needed in most eyes to preserve visual acuity. Different dosing regimens may be used including monthly, pro re nata (PRN), and treat and

Supported in part by NIH Center Core Grant P30EY014801 and Research to Prevent Blindness Unrestricted Grant.

None of the authors has any financial/conflicting interests to disclose.

Reprint requests: Harry W. Flynn, Jr., MD, Department of Ophthalmology, Bascom Palmer Eye Institute University of Miami, Miller School of Medicine, 900 NW 17th Street, Miami, FL 33136; e-mail: hflynn@med.miami.edu

Table 1. Summary of Cases

Case #	Age (Years)	Sex	Agent	# Previous Inj.	Vitreous Culture	Preinfection VA	Postinfection VA	Follow-up Postinfection	# Inj. Postinfection
1	87	Female	Ranibizumab	33	Negative	20/50	20/70	4 years	0
2	89	Male	Bevacizumab	7	Coagulase-negative Staphylococcus	20/60	20/60	22 months	0
3	72	Female	Bevacizumab	4	Dry tap	20/50	20/30	18 months	0
4	81	Male	Triamcinolone with PDT	3	Negative	20/60	20/30	11 years	0
5	75	Male	Bevacizumab	30	Negative	20/50	20/400	2 years	0
6	91	Female	Bevacizumab/ aflibercept	10/15	Coagulase-negative Staphylococcus	20/60	20/70	3 months	0
7	89	Female	Ranibizumab	3	Coagulase-negative Staphylococcus	NA	20/80	6 years	2

PDT, photodynamic therapy.

extend approaches, each with relatively comparable results.<sup>3,4</sup>

In the current case series, patients are described who developed endophthalmitis during the course of treatment for neovascular AMD and later exhibited decreased exudation of choroidal neovascularization.

## Methods

This is a multicenter, retrospective, observational case series review of clinical and imaging findings of seven patients with neovascular AMD who developed endophthalmitis after intravitreal injection and later had changes in the status of their macula and their need for anti-VEGF therapy. The study was granted exemption by the Western Institutional Review Board (IRB, Puyallup, WA, Study Number 19913291) given its retrospective design.

## Case Reports

### Summary of Cases

Four women and three men, ranging in age from 72 years to 91 years, were receiving routine treatment for neovascular AMD. In all patients, the diagnosis of neovascular AMD was made by clinical examination, optical coherence tomography, and sometimes fluorescein or indocyanine green angiography. All patients were treated with a “treat and extend” approach. Three patients were treated with intravitreal bevacizumab, two with intravitreal ranibizumab, one with ranibizumab and aflibercept, and one with photodynamic therapy plus intravitreal triamcinolone (Table 1). The patients had received a total of 1 to 33 treatments over a course of 3 months to 5 years and had a baseline visual acuity of 20/50 to 20/60. Following their last treatment, the patients presented with clinical signs and symptoms of infectious endophthalmitis and were treated with vitreous tap and injection of antibiotics or pars plana vitrectomy (PPV). Four of the seven patients were diagnosed with culture-negative endophthalmitis and three had cultures positive for coagulase-negative Staphylococcus. One patient had two episodes of postinjection endophthalmitis, requiring intravitreal bevacizumab after her first episode of endophthalmitis, but permitting

discontinuation of therapy after her second diagnosis of endophthalmitis 4.5 years later. All seven patients were eventually able to discontinue neovascular AMD treatment after their last episode of endophthalmitis without recurrences.

### Case 1

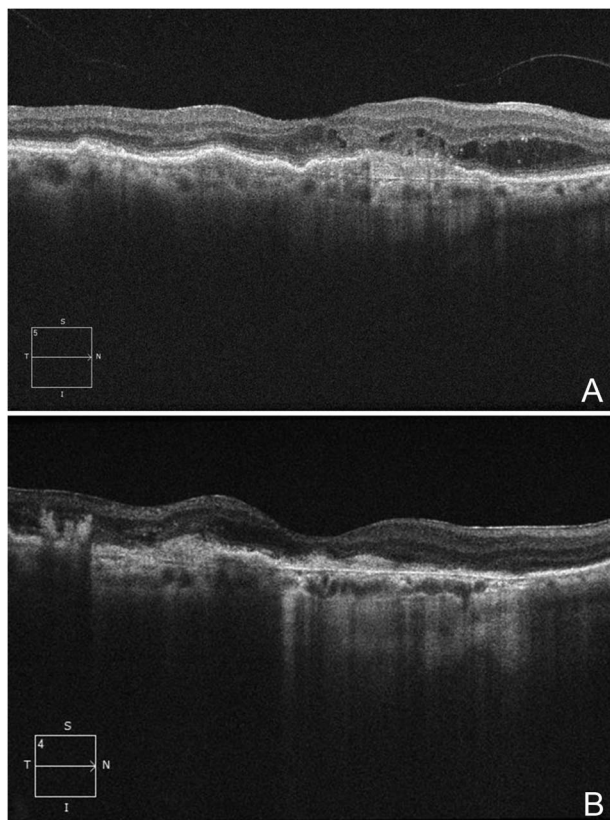
An 87-year-old woman with a history of neovascular AMD treated with 33 previous intravitreal injections of ranibizumab in the right eye over the course of 5 years. She had previously been treated with a treat and extend protocol at a maximal interval of 2 months. Before that injection, her visual acuity was 20/50. Seven days after her final injection, she presented with blurred vision and pain. Visual acuity was 3/200. Slit-lamp biomicroscopy revealed 2 to 3+ vitreous haze without hypopyon. The patient was treated with a PPV and intravitreal injection of 1-mg vancomycin, 0.25-mg ceftazidime, and 400- $\mu$ g dexamethasone. Vitreous culture was negative. After resolution of endophthalmitis, the patient has not required another intravitreal injection for her neovascular AMD, and her vision has remained stable at 20/70 over the last 4 years of follow-up (Figure 1).

### Case 2

An 89-year-old man with a history of neovascular AMD treated previously with seven injections of intravitreal bevacizumab had stable visual acuity of 20/60 over the course of 19 months of therapy using a PRN regimen ranging from 6 weeks to 5-month intervals. Two days after the patient's last injection, the patient developed blurred vision, pain, and an afferent pupillary defect. Visual acuity was reduced to hand motions. Slit-lamp biomicroscopy demonstrated corneal edema, hypopyon, and dense vitritis. The patient was treated with vitreous tap and injection of 1-mg vancomycin and 2.25-mg ceftazidime. Culture was positive for coagulase-negative Staphylococcus. Three months after resolution of his infection, the patient's vision returned to 20/60 and was maintained at 20/60 without injections 12 months later. Optical coherence tomography demonstrated RPE scarring and persistent mild CME without subretinal fluid until 22 months later when subretinal fluid and hemorrhage were identified. The patient refused any additional injections.

### Case 3

A 72-year-old woman with a history of exudative AMD had received four intravitreal bevacizumab injections for over 5 months. She was treated with a monthly protocol for the first injections and



**Fig. 1.** Regression of active exudation in an 87-year-old woman in neovascular AMD after postinjection endophthalmitis (Case 1). **A.** Optical coherence tomography of the right eye two years before endophthalmitis shows a hyperreflective vascular pigment epithelial detachment and intraretinal fluid as well as a small epiretinal membrane. **B.** Optical coherence tomography of the right eye 4 years after post-injection endophthalmitis shows trace subretinal and intraretinal fluid, resolution of the neovascular membrane, and atrophy.

received her fourth injection at an interval of 2 months. At the time of her last injection, visual acuity was 20/50. Four days later, she developed pain, redness, and blurred vision. Visual acuity was 20/400. Slit-lamp biomicroscopy revealed 1+ cells in the anterior chamber and vitritis but no hypopyon. A vitreous tap was attempted but was dry. Following the tap, the eye received intravitreal injection of 1-mg vancomycin and 2.25-mg ceftazidime. Three months later, the patient's vision recovered to 20/50. She then developed recurrent exudation and required continued treatment with intravitreal bevacizumab for 4.5 more years. After having received 41 additional injections, she developed a second episode of endophthalmitis. Vitreous tap was culture-negative, and the patient was again treated with 1-mg vancomycin and 2.25-mg ceftazidime. One and a half years since the second episode of endophthalmitis, the patient's visual acuity is 20/30 and the neovascular regressed, eliminating the need for additional injections (Figure 2).

#### Case 4

An 81-year-old man with a history of neovascular AMD in his right eye was treated with three sessions of photodynamic therapy and intravitreal triamcinolone (before the availability of anti-VEGF therapy). At his last treatment, his visual acuity was 20/60. One day

after injection, the patient developed blurred vision. Best-corrected visual acuity was 20/400. Slit-lamp biomicroscopy showed 2+ cells in the anterior chamber and 4+ vitreous haze. The patient was treated with PPV and injection of 1-mg vancomycin, 2.25-mg ceftazidime, and 400- $\mu$ g dexamethasone. Culture results were negative. The patient has not required treatment for neovascular AMD after resolution of his infection and has been followed for 11 years with last visual acuity 20/30.

#### Case 5

A 75-year-old man with a history of neovascular AMD received 30 intravitreal injections of bevacizumab in his right eye over 5 years every 4 to 8 weeks based on a treat and extend regimen. The patient developed pain and redness 4 days after his last injection with vision reduced to count fingers. Before this injection, his visual acuity was stable at 20/150. Slit-lamp biomicroscopy revealed corneal edema, hypopyon, and vitritis. Vitreous tap was negative for organisms. The patient was treated with intravitreal injections of 1-mg vancomycin and 2.25-mg ceftazidime. Visual acuity decreased to 20/400 after endophthalmitis because of development of a dense posterior subcapsular cataract, although his last optical coherence tomography showed nearly a 50% reduction in central thickness. No additional treatment for neovascular AMD was required after endophthalmitis until the patient's death 2 years later.

#### Case 6

A 91-year-old woman with a history of neovascular AMD received 10 bevacizumab and 15 aflibercept injections every 6 to 8 weeks over the course of 4 years in her right eye. Visual acuity before her last injection was 20/60. Two days after treatment, she developed decreasing vision and pain. Slit-lamp biomicroscopy revealed 4+ cells in the anterior chamber and 2+ vitreous haze. Vitreous tap was positive for coagulase-negative *Staphylococcus*. The patient was treated with injection of 1-mg vancomycin and 2.25-mg ceftazidime. The next day, PPV was performed. The patient has been followed for 3 months after endophthalmitis and has a visual acuity of 20/70 without the need for further injections.

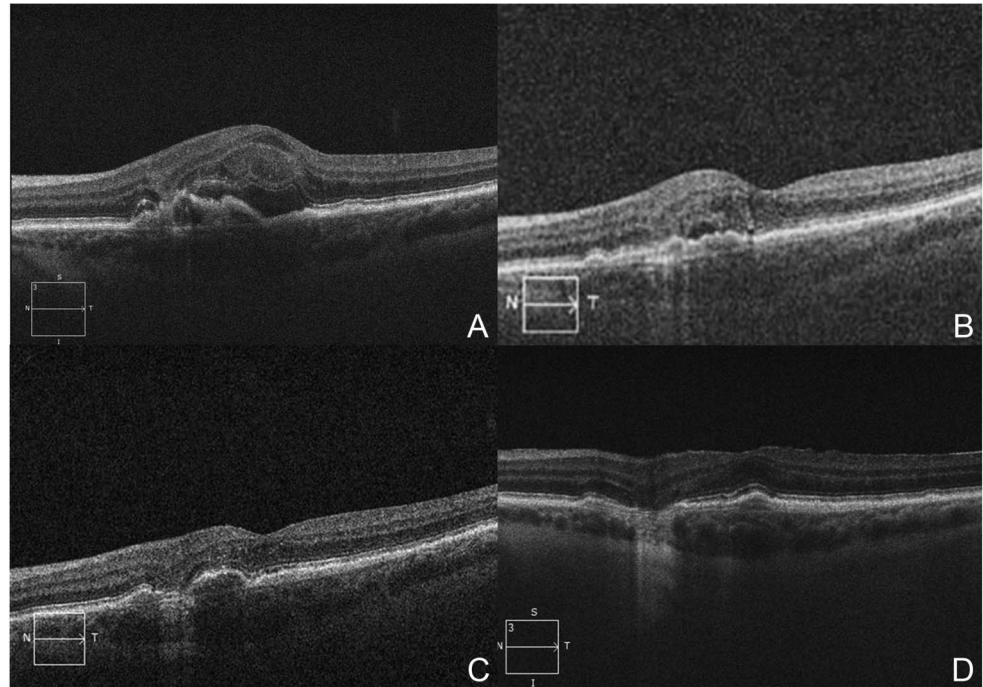
#### Case 7

An 89-year-old woman was treated with three ranibizumab injections for neovascular AMD in the left eye over the course of 3 months. After her last injection, she developed pain, redness, and decreased vision. Visual acuity was light perception. Slit-lamp biomicroscopy showed corneal edema, hypopyon, and vitritis. A vitreous tap returned positive for coagulase-negative *Staphylococcus*, and the patient was treated with intravitreal injections of 1-mg vancomycin, 2.25-mg ceftazidime, and 0.4-mg/mL dexamethasone. After resolution of her infection, the patient received two additional ranibizumab injections at 3 months and 5 months after endophthalmitis. After these injections, no treatment for neovascular AMD was required. The patient's current visual acuity, 6 years after endophthalmitis, is 20/80.

## Discussion

Endophthalmitis is a serious adverse event that often results in poor visual outcomes.<sup>5</sup> The eyes described in this case report had resolution of their infections with

**Fig. 2.** Regression of choroidal neovascularization in a 72-year-old woman with a history of neovascular AMD (Case 3). **A.** Optical coherence tomography 5 months after the first episode of endophthalmitis discloses a vascular pigment epithelial detachment with subretinal and intraretinal fluid. **B.** Optical coherence tomography 3 months after the first episode of endophthalmitis shows reduced intraretinal and subretinal fluid. **C.** Optical coherence tomography 20 months after the second episode of endophthalmitis shows a moderate pigment epithelial detachment with adjacent trace subretinal fluid. **D.** Optical coherence tomography 18 months after the second episode of endophthalmitis reveals resolved macular edema with a focal area of geographic atrophy.



concomitant regression of their exudative neovascular membranes. Of note, all the eyes in this series were infected with either coagulase-negative *Staphylococcus* or had negative taps, and there were no eyes infected with *Streptococcus* that has been associated with less favorable visual outcomes.<sup>6</sup>

In 2010, two patients were described with neovascular AMD that developed endophthalmitis after intravitreal anti-VEGF therapy.<sup>7</sup> Both eyes were treated with PPV and injection of intravitreal antibiotics and had negative cultures. Subsequent examinations demonstrated regression of neovascularization and no further need for treatment with anti-VEGF. The first case maintained favorable visual acuity, and the choroidal neovascular membrane resolved leaving behind geographic atrophy. In the second case, the patient developed poor visual acuity, but the choroidal neovascular membrane also resolved, also leaving behind a large area of atrophy. Of note, both of these patients were treated with PPV, and the authors postulated that removal of the vitreous may have contributed to the regression of neovascularization through reduction of VEGF levels and improvement in intravitreal oxygenation.<sup>8</sup>

In the current series, most patients were treated with vitreous tap alone but still had a similar result. In a separate study by Yoon et al,<sup>9</sup> it was reported that eyes treated with triamcinolone that then developed postinjection endophthalmitis had less macular edema

after resolution of the infection, although this study was limited to noninfectious endophthalmitis. More recently, Kally et al<sup>10</sup> described a case of resolution of subretinal fluid after postinjection endophthalmitis in a patient with neovascular AMD. The authors postulated that upregulation of complement factor H, which has been associated with a protective effect on the development of AMD, during the infection could be a biochemical explanation for the regression in exudation.

The mechanisms for regression of exudation after infectious endophthalmitis are unclear. It is believed that an angiostatic inflammatory state can be reached in cases of chronic inflammation where there are high levels of proinflammatory cytokines such as  $\text{IFN}\alpha/\gamma$ ,  $\text{TNF}\alpha$ , and  $\text{IL-1}\alpha/\beta$ .<sup>11</sup> These cytokines induce endothelial cells to secrete guanylate binding protein-1 (GBP-1), which exerts antiangiogenic effects such as inhibition of endothelial cell proliferation, migration, and invasion. Thus, it is possible that the induction of an antiangiogenic retinal environment during the active phase of endophthalmitis contributed to a decreased and persistent antiangiogenic effect, although this hypothesis is highly speculative. It is unknown what effect the actual microbe may have had on the vascular membrane. It is well known, however, that chronic inflammatory diseases<sup>12</sup> may be complicated by the development of choroidal neovascularization and even infectious conditions, such as endogenous endophthalmitis,<sup>13–15</sup> can lead to

neovascularization, so the mechanism of regression in this case series is unclear.

Thus, a key area for future investigation is whether our observation is more driven by the effect of the infectious process on scar formation or its effect on exudation. Optical coherence tomography angiography may be a useful adjunct to study these types of cases to determine whether there are also changes in lesion size or regression of choroidal neovascularization or whether this is simply an arrest in exudation without a change in vascular anatomy. In many cases where neovascular AMD arrests, vision may ultimately be limited by progression of atrophy or disciform scar. The patients in this series did not appear to develop more prominent scarring, yet many did develop atrophy, limiting the visual acuity. Given its observational nature, it is not possible from to determine the effect of the infectious process on the development of atrophy.

A significant limitation to this study is its retrospective nature, small sample size, author selection bias, and lack of a comparison group. It may be possible that the regression on neovascularization simply represented the natural progression of these cases of neovascular AMD. Although less common, some patients may exhibit long-term stability after just a short duration of intravitreal anti-VEGF therapy.<sup>3</sup> Prospective or retrospective comparative studies are needed to investigate this observation in the future.

### Conclusions

Some patients who develop postprocedure endophthalmitis may experience regression of choroidal neovascularization after successful treatment and resolution of endophthalmitis. The mechanisms involved in this regression are poorly understood, but these patients may require less-rigid schedules for intravitreal injection. These cases are intriguing, and further investigation of the mechanisms of may provide insight into future treatment approaches to this disease.

**Key words:** neovascular age-related macular degeneration, endophthalmitis.

### References

1. Gregori NZ, Flynn HW Jr, Schwartz SG, et al. Current infectious endophthalmitis rates after intravitreal injections of anti-vascular endothelial growth factor agents and outcomes of treatment. *Ophthalmic Surg Lasers Imaging Retina* 2015;46:643–648.
2. Moshfeghi AA, Rosenfeld PJ, Flynn HW Jr, et al. Endophthalmitis after intravitreal vascular [corrected] endothelial growth factor antagonists: a six-year experience at a university referral center. *Retina* 2011;31:662–668.
3. CATT Research Group, Martin DF, Martin DF, Maguire MG, et al. Ranibizumab and bevacizumab for neovascular age-related macular degeneration. *N Engl J Med* 2011;364:1897–1908.
4. Silva R, Berta A, Larsen M, et al. TREND Study Group. Treat-and-Extend versus monthly regimen in neovascular age-related macular degeneration: results with ranibizumab from the TREND study. *Ophthalmology* 2017;125:57–65.
5. Fileta JB, Scott IU, Flynn HW Jr. Meta-analysis of infectious endophthalmitis after intravitreal injection of anti-vascular endothelial growth factor agents. *Ophthalmic Surg Lasers Imaging Retina* 2014;45:143–149.
6. Chen E, Lin MY, Cox J, Brown DM. Endophthalmitis after intravitreal injection: the importance of viridans streptococci. *Retina* 2011;31:1525–1533.
7. Emoto H, Emoto Y, Lim JI, et al. Regression of choroidal neovascularization after vitrectomy for postinjection endophthalmitis. *Retin Cases Brief Rep* 2010;4:312–316.
8. Stefánsson E. Ocular oxygenation and the treatment of diabetic retinopathy. *Surv Ophthalmol* 2006;51:364–380.
9. Yoon SJ, Rhee DY, Marx JL, et al. Anatomic and visual outcomes of noninfectious endophthalmitis after intravitreal triamcinolone. *Am J Ophthalmol* 2009;147:1031–1036.
10. Kally PM, Sidikaro Y, McCannel CA. Resolution of treatment-resistant subretinal fluid in a patient with exudative age-related macular degeneration following endophthalmitis. *Retin Cases Brief Rep* 2017;11:316–318.
11. Hammon M, Herrmann M, Bleiziffer O, et al. Role of guanylate binding protein-1 in vascular defects associated with chronic inflammatory diseases. *J Cell Mol Med* 2011;15:1582–1592.
12. Rouvas A, Petrou P, Douvali M, et al. Intravitreal ranibizumab for the treatment of inflammatory choroidal neovascularization. *Retina* 2011;31:871–879.
13. Fecko AM, Ho LY, Walsh MK, Williams GA. Intravitreal bevacizumab and ranibizumab for choroidal neovascularization secondary to endogenous endophthalmitis. *Retin Cases Brief Rep* 2011;5:229–232.
14. Fong AH, Li KK, Jon HC, et al. Choroidal neovascularization secondary to *Klebsiella pneumoniae* endogenous abscess and endophthalmitis. *Clin Exp Ophthalmol* 2009;37:239–240.
15. Tedeschi M, Varano M, Schiano Lomoriello D, et al. Photodynamic therapy outcomes in a case of macular choroidal neovascularization secondary to *Candida* endophthalmitis. *Eur J Ophthalmol* 2007;17:124–127.